



FP702: CHOROIDDAL REMODELLING IN POLYPOIDAL CHOROIDDAL VASCULOPATHY AFTER TREATMENT WITH PHOTODYNAMIC THERAPY

Jay Sheth¹, A. Jay Chhablani², A. Giridhar¹, Shruti Chandra¹.

(1) Department of Vitreo-Retinal Services, Giridhar Eye Institute, India. (2) Department of Vitreo-Retinal Services, LVPEI, India
No Financial Disclosures

Polypoidal choroidal vasculopathy (PCV) forms a part of the pachychoroid spectrum disease exhibiting excellent treatment response to photodynamic therapy (PDT) as it targets the primary pathology involving the choroid

AIM

- 1) To evaluate the retinal and choroidal morphological changes after treatment of PCV with PDT in combination with intravitreal ranibizumab.
- 2) To assess the visual acuity outcomes at the end of six months of treatment.

MATERIALS AND METHODS

- Retrospective analysis of 8 eyes of PCV undergoing full fluence PDT + 3 loading doses of ranibizumab, followed by PRN regimen.
- All eyes underwent multimodal imaging including enhanced-depth imaging optical coherence tomography (EDI-OCT), fundus autofluorescence (FAF), digital fluorescein angiography (DFA) and indocyanine green angiography (ICGA) on Spectralis at baseline
- At each monthly follow-up visit upto 6 months, only OCT and FAF were repeated
- Changes in BCVA, subfoveal choroidal thickness (SFCT), CT at level of pachyvessel (CTPv), choroidal vascularity index (CVI), choroidal area (CA), intraretinal fluid (IRF), subretinal fluid (SRF), along with dimensions of PED (height, base diameter, area) and shallow irregular PED (Double layer sign: DLS) were analyzed at baseline and at 6 months

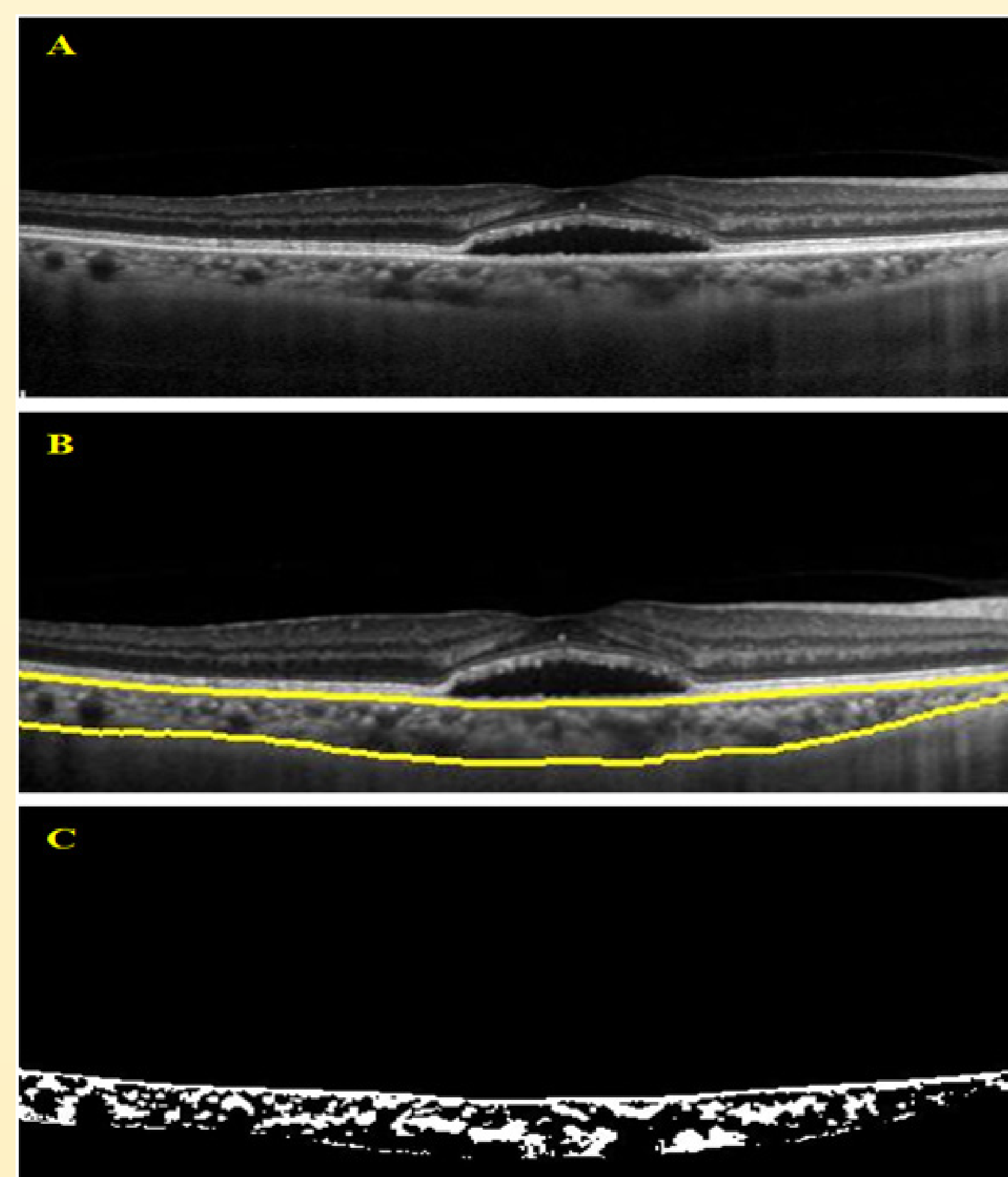


Figure 1: Spectral domain optical coherence tomography (SD-OCT) of a patient at baseline (A) on which choroidal segmentation is performed using an automated algorithm (B). C represents the binarized image illustrating the luminal areas (Black region) and the interstitial areas (White region) that is used to calculate the choroidal vascularity index (CVI).

Parameter	Baseline	6 months post Combination therapy (PDT + IVR)	p-value
BCVA	0.49 ± 0.04	0.42 ± 0.03	0.4
SFCT (μm)	298.50 ± 78.18	248.25 ± 65.61	0.002*
CTPv (μm)	276.12 ± 33.88	233.12 ± 41.28	0.001*
Choroidal area (mm ²)	0.98 ± 0.18	0.98 ± 0.23	0.81
CVI(mm ²)	0.59 ± 0.02	0.58 ± 0.04	0.14
SRF Height(μm)	166.62 ± 96.68	65.50 ± 94.06	0.005*
PED Height(μm)	295.38 ± 201.61	136.62 ± 178.15	0.002*
PED Width(μm)	1103.12 ± 899.28	973.88 ± 1018.24	0.31
PED Area	0.24 ± 0.25	0.14 ± 0.18	0.03*
DLS Height(μm)	65.75 ± 35.17	40.00 ± 37.47	0.04*
DLS Width(μm)	1426.25 ± 989.06	1227.12 ± 1044.42	0.63

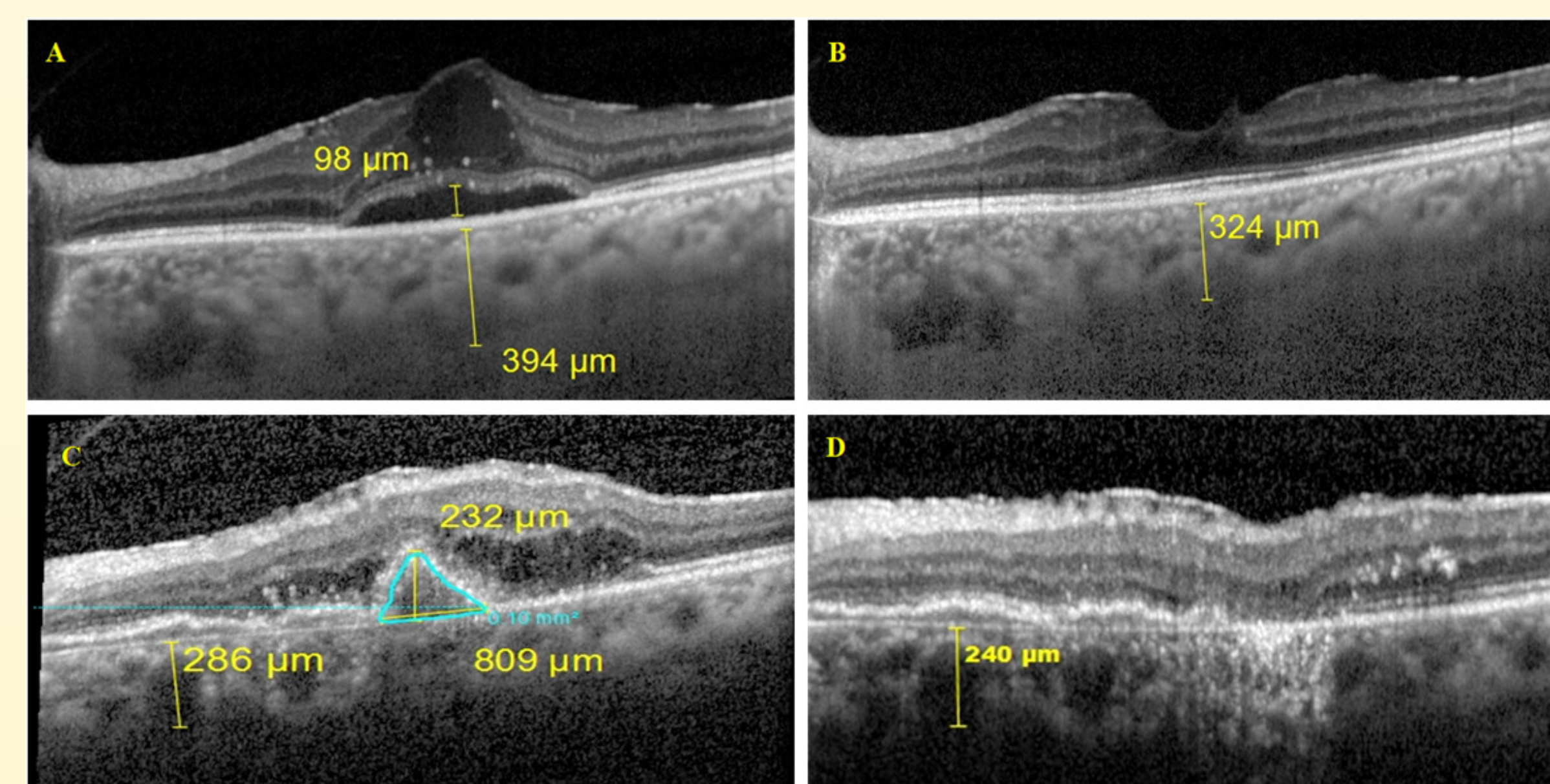


Figure 2: SD-OCT of a patient illustrating complete resolution of intraretinal and subretinal fluid with substantial reduction in choroidal thickness at six months post-PDT + 5 IVR (B) as compared to baseline (A). C shows the dimensions of the PED at baseline with measurement of choroidal thickness at the level of pachyvessel (CTPv; 286 μm) which is significantly reduced six months following the combination therapy (240 μm) along with complete resolution of the PED and IRF (D).

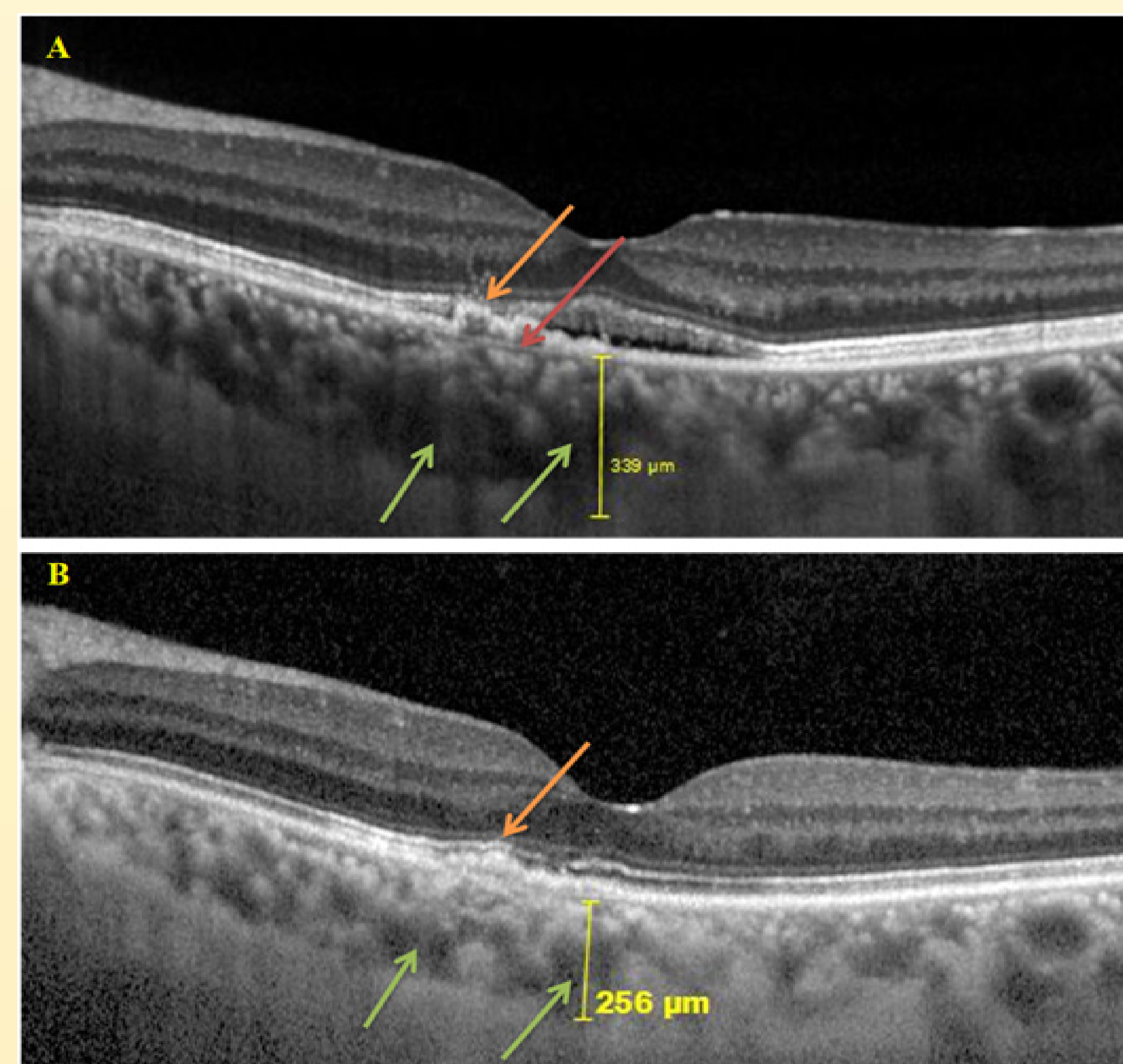


Figure 3: SD-OCT of a patient illustrating significant reduction in CT, complete resolution of DLS (Orange arrow) and reduction in dimension of choroidal vessels (Green arrows) at six months post-PDT + 3 IVR (B) as compared to baseline (A).

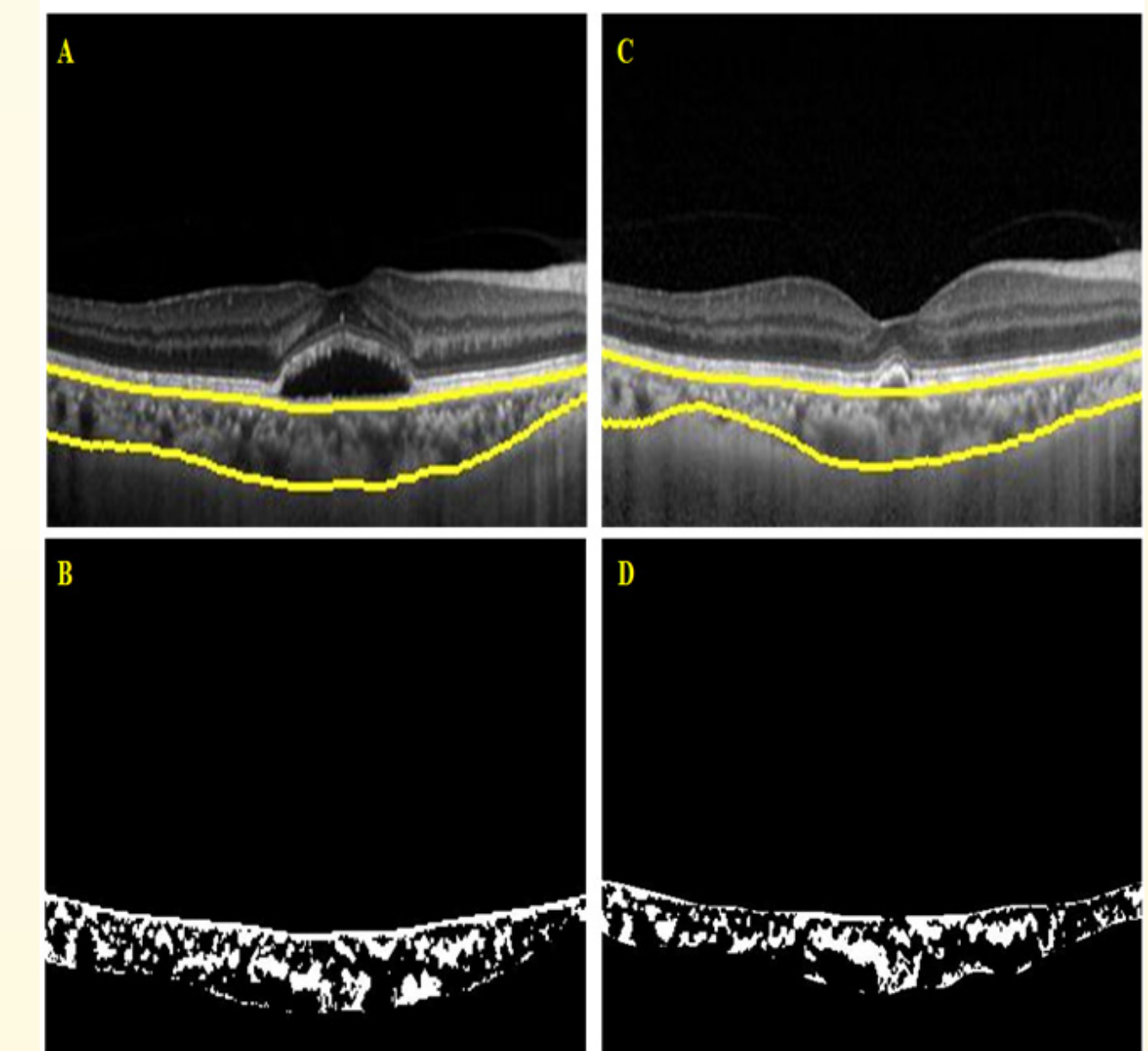


Figure 4: SDOCT of a patient at baseline (A) and at six months post-PDT + 4IVR (C) on which choroidal segmentation is performed using an automated algorithm. B and D are the respective binarized images used to calculate the choroidal vascularity index (CVI)

OTHER KEY RESULTS

- The mean number of injections over 6 months was 4.88 ± 0.99 with average PDT spot size being 3668.75 ± 847.24 μm
- All eight eyes had pachyvessel at baseline, of which three eyes showed resolution of the same at six months
- Complete resolution of PED was noted in 3 out of 7 eyes while the DLS resolved in 2 out of 7 eyes respectively
- 66.33%(2/3 eyes) and 62.5% (5/8 eyes) of eyes had complete resolution of IRF and SRF respectively

DISCUSSION

We demonstrate a significant reduction in SFCT post combination therapy with PDT + IVL similar to shown by Lai et al¹

Additionally, for the first time in literature, we evaluated the choroidal thickness at the level of pachyvessel (CTPv) and observed an analogous reduction in its magnitude too at 6 months

Reduction in PED height post PDT + IV Aflibercept + IVTA has been documented by Sakai et al²

In the current study, we additionally performed evaluation of PED base diameter, PED area and changes in magnitude of DLS (shallow irregular PED) dimensions, and intra-retinal fluid, which have not been documented in literature till date

CONCLUSION

Photodynamic therapy is associated with an improvement in retinal and choroidal morphology in eyes with polypoidal choroidal vasculopathy

It is associated with stabilization of choroidal vascularity indicative of a near equal reduction in the vascular and stromal component of the choroid

Additionally, it is beneficial in achieving a dry macula, maintaining stable visual acuity with an acceptable safety profile