

Transconjunctival retractor plication -A scar less approach to Entropion correction

Dr Joyeeta Das ,MBBS,DNB

Consultant surgeon –Orbit & Oculoplasty


Disha Eye Hospitals, Barrackpore , Kolkata ,INDIA

Co-author :
Dr Nibedita Das,DNB,FICO



FP1457

No financial interest

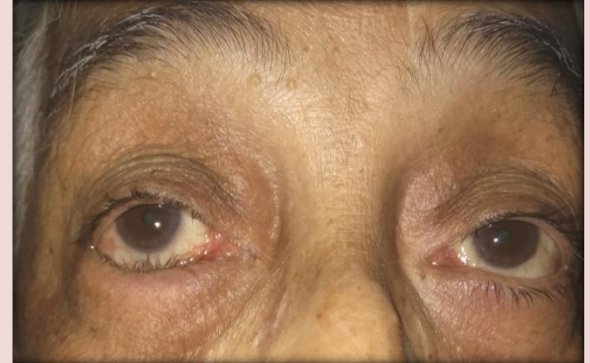

Introduction

- Lower lid involutational entropion is a common ailment affecting the elderly population ³

- It results in ³

- chronic ocular surface irritation
- punctate keratopathy
- corneal pannus formation with decreased visual acuity



- The pathophysiology are ⁴

- a. Attenuation of lower lid retractors
- b. Horizontal lid laxity
- c. Overriding of preseptal orbicularis

Introduction

- Surgical corrections are mainstay of treatment
- Numerous techniques evolved over the century with various success rates
- The most popular and successful technique of entropion repair- Retractor plication [Jones procedure]
- Plication can be achieved through
 - **Cutaneous Incision (External)**
 - **Internally through a transconjunctival approach**
- Transconjunctival entropion repair reported by few authors mostly from western authors
- No such study yet reported from Indian subcontinent

Purpose

To present the outcome of surgical correction of involutional lower lid entropion through transconjunctival route on Indian population

Methods

Study design

- Retrospective single surgeon study

Study period

- April 2016- April 2018

Place of study

- Disha Eye Hospital ,Kolkata India

Methods

Inclusion criteria

- Lower lid involucional entropion

Exclusion criteria

- Entropion due to ocular cicatricial disease
- Posterior lamellar shortening
- Patient with peri-ocular skin ailments

Surgical steps

Lower lid traction suture



A Conjunctival incision 2 mm below inferior tarsal border - lat canthus to punctum



B conjunctival flap was elevated



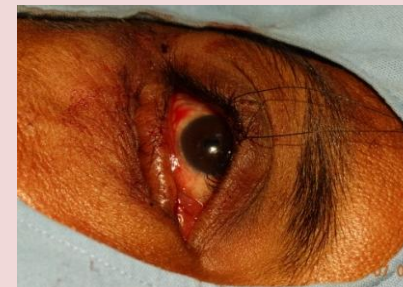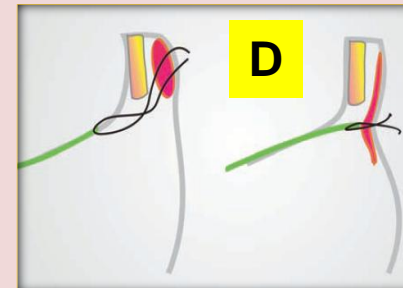
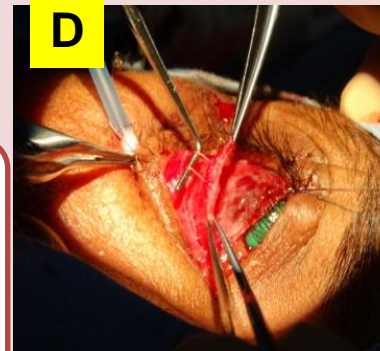
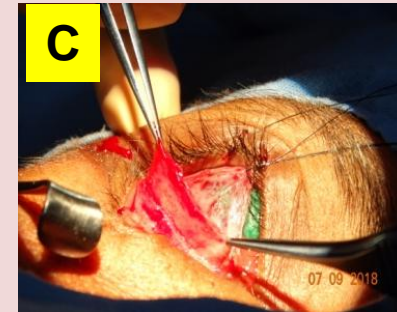
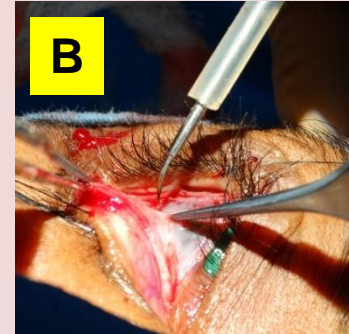
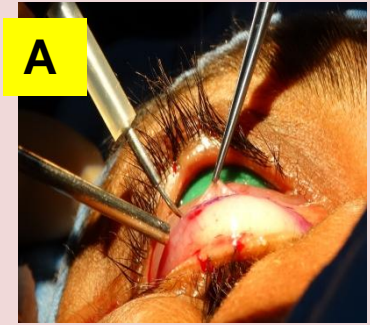C Lower eyelid retractors were identified

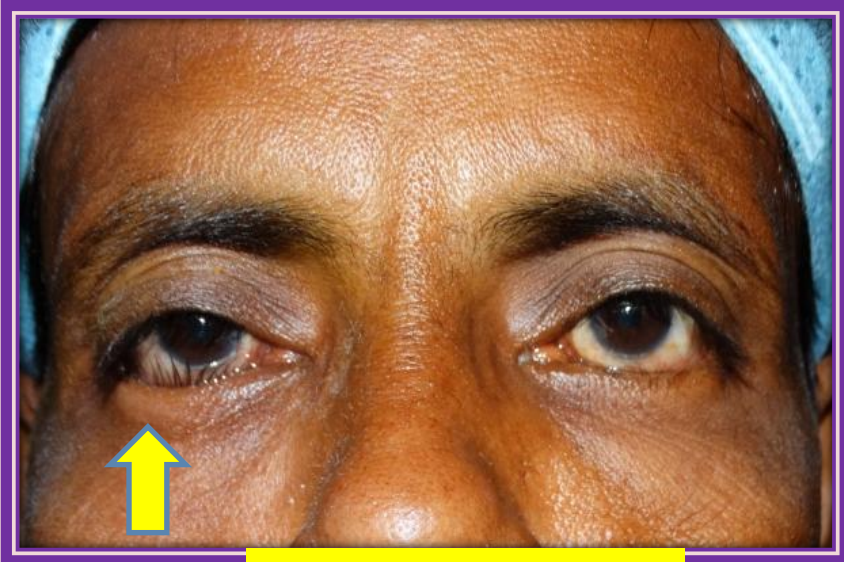

D Lower eyelid retractors then reattached to the anterior inferior border of the tarsus using three interrupted 5-0 polyglactin sutures

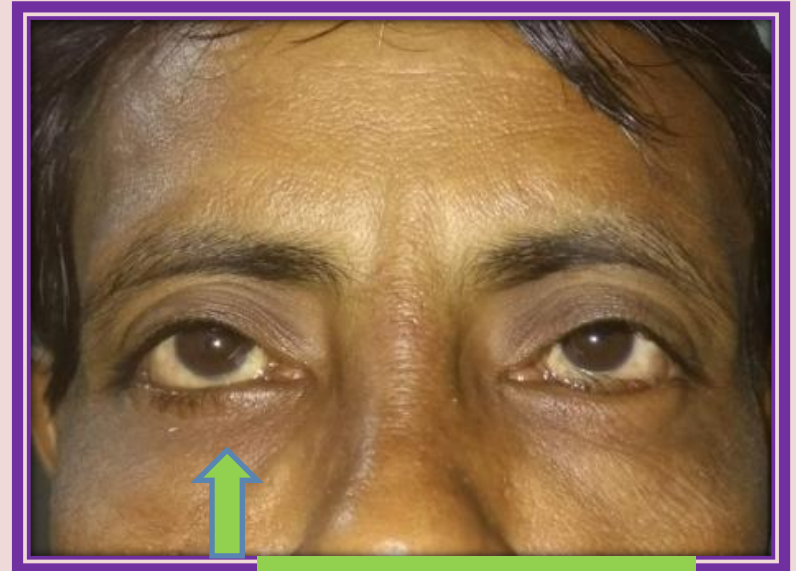

If there are horizontal laxity present lateral tarsal strip[LTS] done

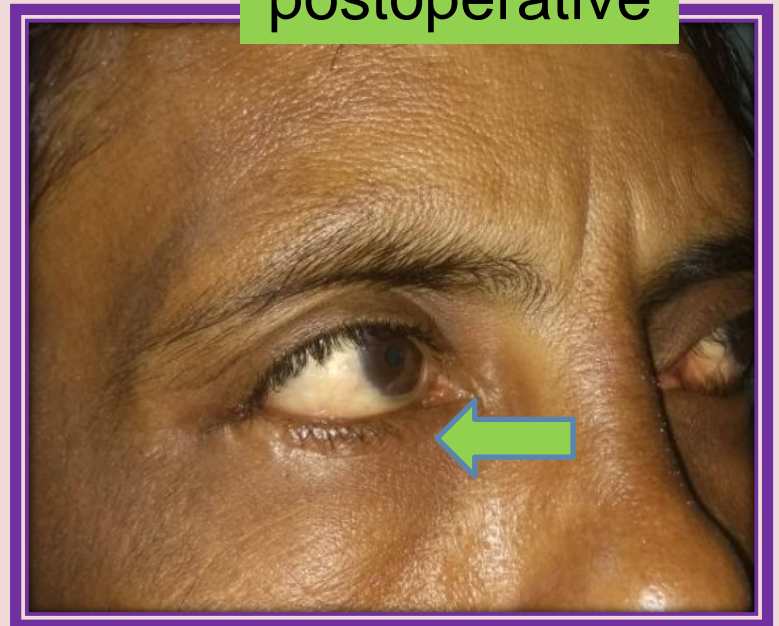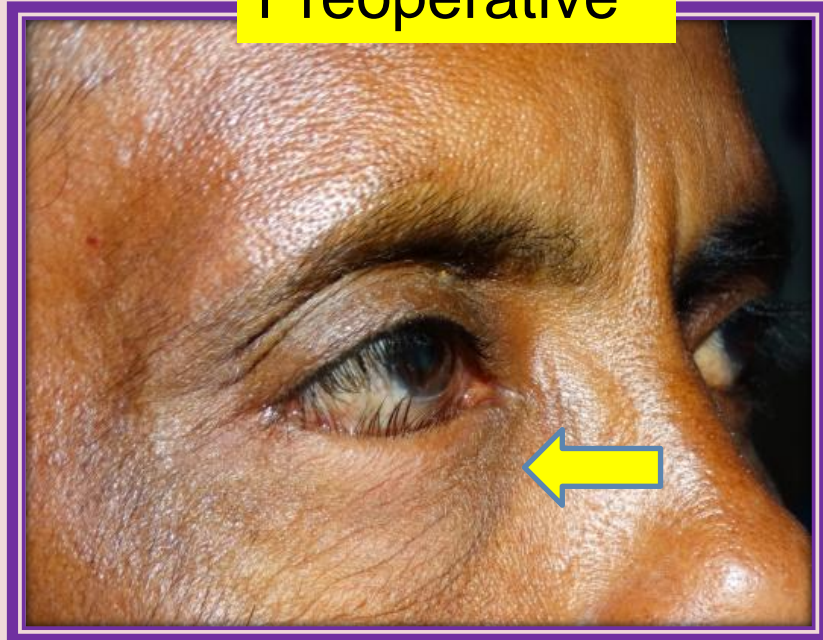




Preoperative



postoperative

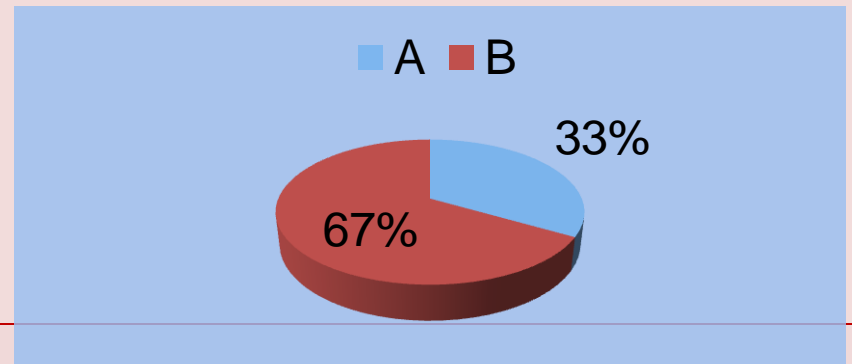


Results

- Total cases (N) = 27 lids of 23 patients [M:F 12:11]
- Mean age : 65.08+/- 8.5 years
- Mean follow-up : 19.4 +/- 3 months [min 6 months , maximum 26 month]

Procedure done :

- A. Transconjunctival lower lid retractor plication only – 9 lids [33.33%]
- B. Transconjunctival retractor plication with lateral tarsal strip – 18 lids [66.66%]



Results

	1 month	6 th month	> 6 th month
Successful outcome	27 [100%]	27 [100%]	26 [96.3 %]
Recurrence	0	0	1 [3.7%]

Successful outcome defined as complete resolution of lower lid entropion with proper apposition of posterior sharp lid with globe

Discussion

- Transconjunctival entropion surgery introduced by Dresner et al in 1993
- Since then only few authors have shared their experience of this technique
- Transconjunctival retractor plication is highly efficacious technique with success rate ranging from 84% - 97.3% [2,3,4]

Discussion

- The success of the procedure depends on addressing 3 components ^[4]
 - Plication of lower lid retractor
 - Horizontal lid tightening
 - Preseptal Orbicularis muscle excision
- Though our technique differs from Dresner et al technique [no orbicularis excision], the final long term success is comparable ⁴
- In our series the final success rate are 96.3%

Discussion

- Advantages of this technique observed in our series
 - No skin scar
 - Relatively bloodless dissection
 - Direct exposure of retractor complex
 - No postoperative scleral show and lower lid retraction
 - Lower blepharoplasty can also be done through same incision
- Disadvantage of the technique -
 - Technically difficult - demands more precision

Conclusion

Transconjunctival retractor plication is highly efficacious ,scarless technique of lower lid involutional entropion correction with full restoration of lower lid anatomy and relatively low recurrence rate

References

1. Jones LT, Reeh MJ, Wobig JL. Senile entropion. A new concept for correction. Am J Ophthalmol 1972;74:327–9
2. Ben Simon GJ, Molina M, Schwarcz RM, et al. External (subciliary) vs internal (transconjunctival) involutional entropion repair. Am J Ophthalmol 2005;139:482–7
3. Khan SJ, Meyer DR. Transconjunctival lower eyelid involutional entropion repair—long-term follow-up and efficacy Ophthalmology 2002;109:2112–7
4. Dresner SC, Karesh JW. Transconjunctival entropion repair Arch Ophthalmol 1993;111(8):1144–1148

Thank you for your kind attention