

A rare case of optic nerve transection with retinal detachment due to road traffic accident

Author : Dr. Mauli Shah

Co-Authors : Dr. Sharda Punjabi, Dr. Lipa Mohanty, Dr. Saloni Patel

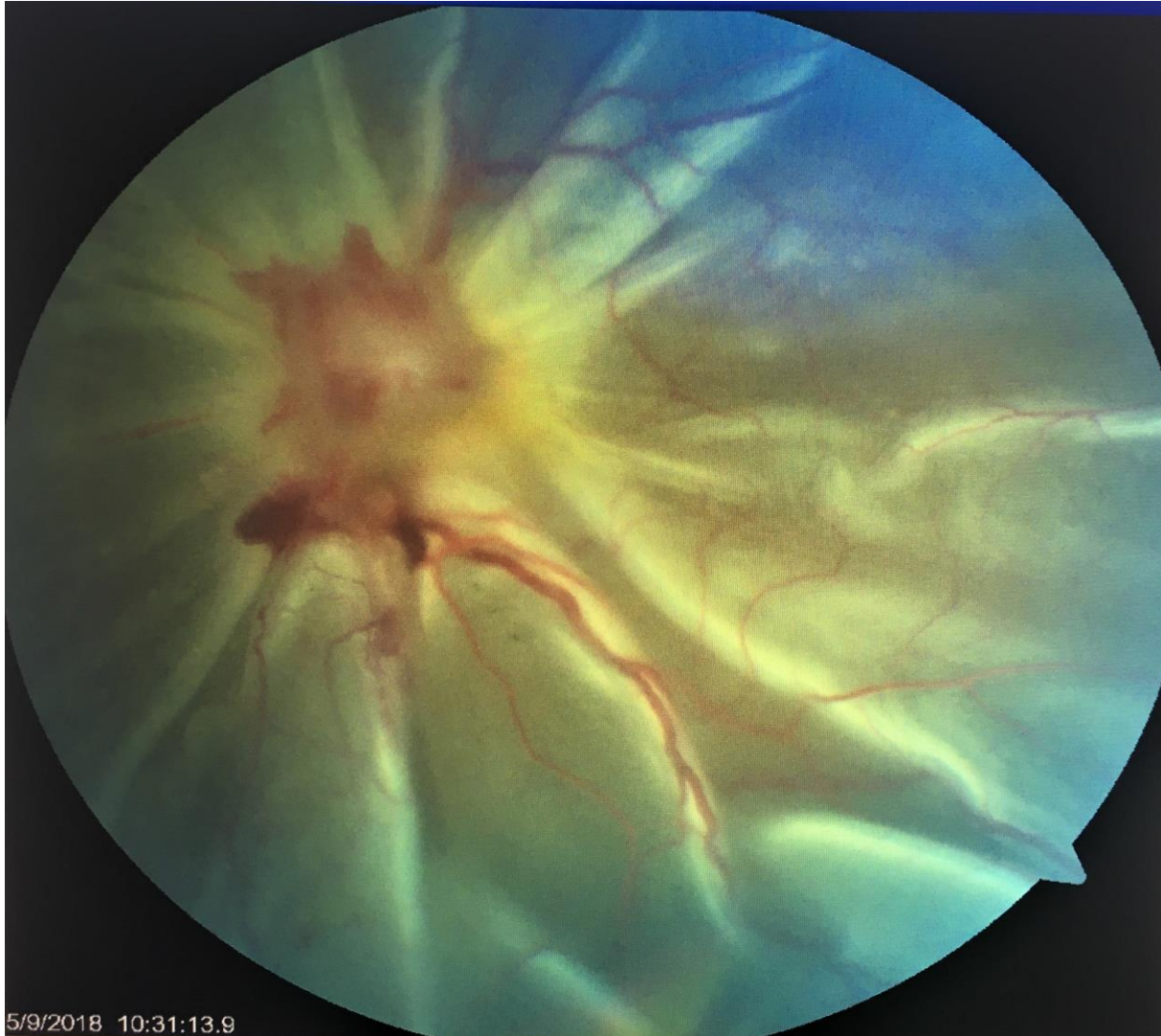
Introduction

- Traumatic optic neuropathy (TON) occurs in 0.5-5.0% of all closed head injuries.
- It is divided into direct and indirect injuries, depending on the mechanism.
- Direct TON occurs when an object physically disrupts/damages the optic nerve, e.g. optic nerve transection.
- It is relatively rare compared to indirect TON, in which concussive forces are transmitted to the nerve, often from blunt trauma or deceleration injuries.

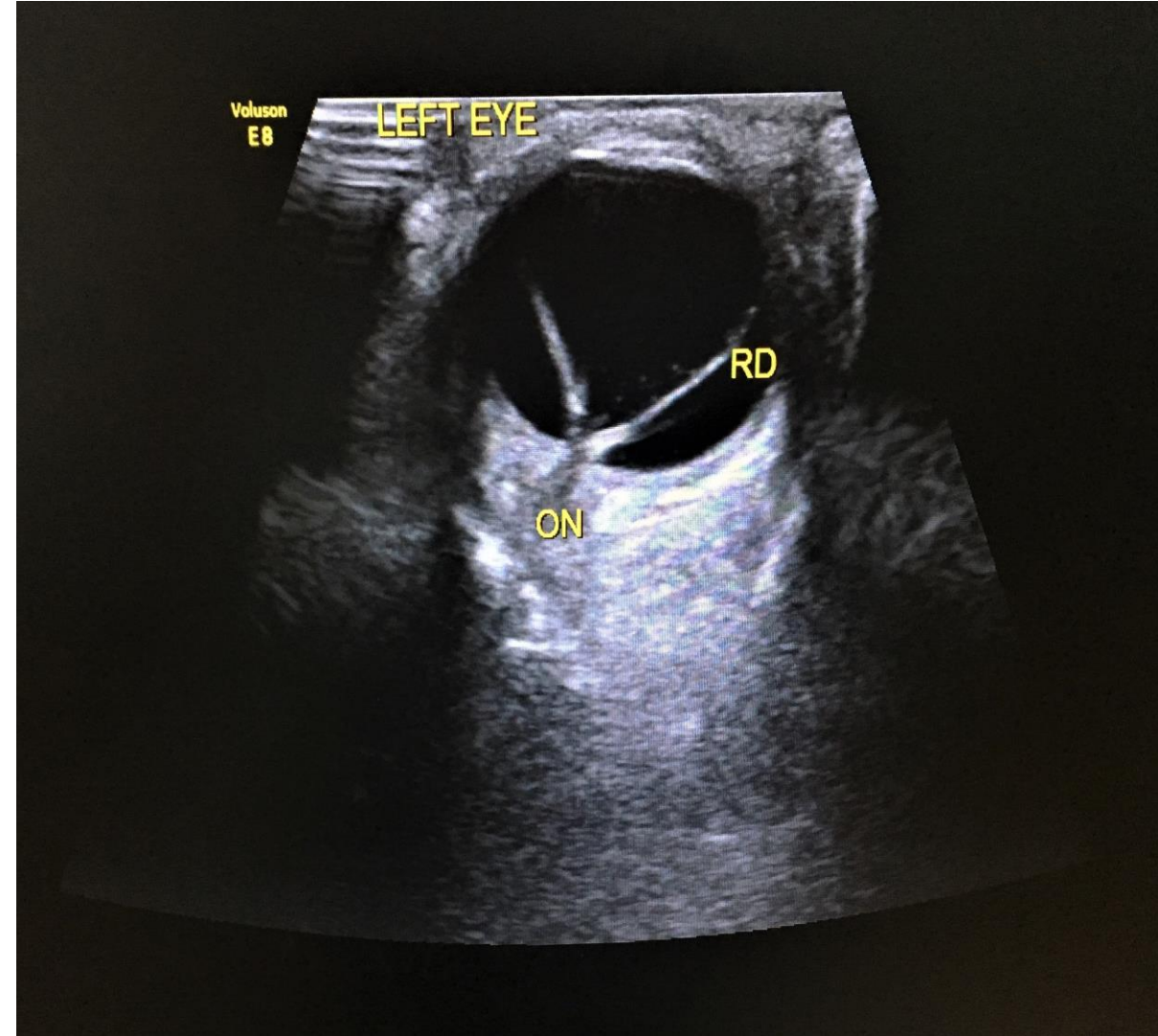
Case Details

- A 22 year old male with complaint of unilateral complete loss of vision following road traffic accident presented after 3 months of incident.
- He had fractures of floor, medial wall and lateral wall of LE orbit along with fractures of all the walls of maxillary sinus of left side.
- VA (RE) 6/6 , VA (LE) No perception of light
- LE – Direct pupillary light reflex absent.
- Indirect ophthalmoscopy and fundus photography was done suggestive of optic nerve head pulled anteriorly and lying in the vitreous with total retinal detachment involving the macula.
- USG B-scan, MRI & CT scan were done to confirm the diagnosis.

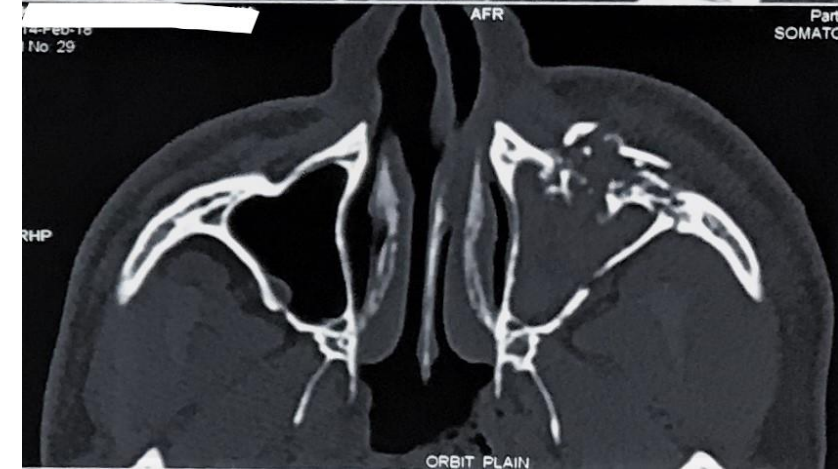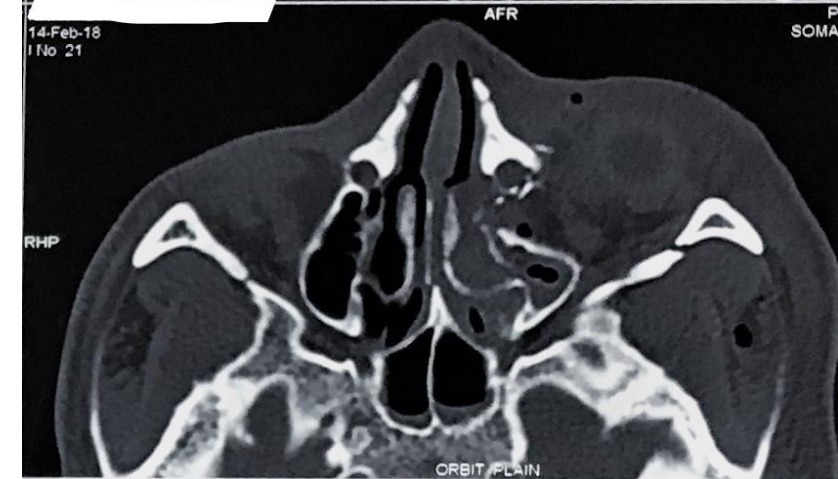
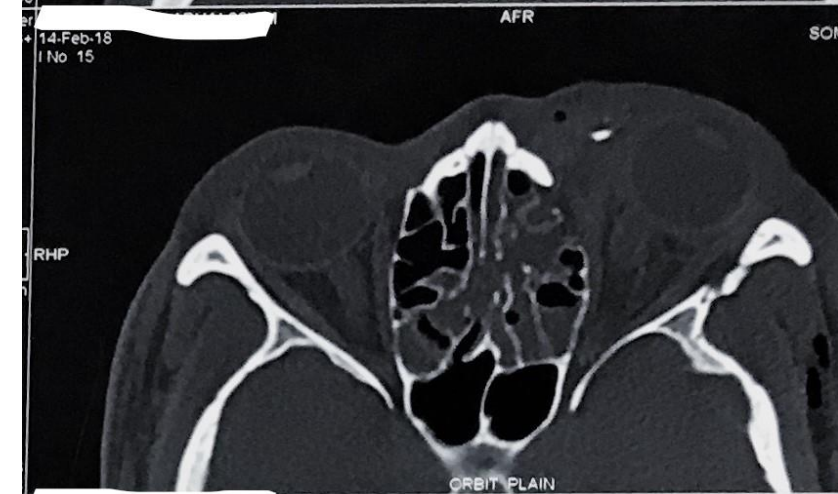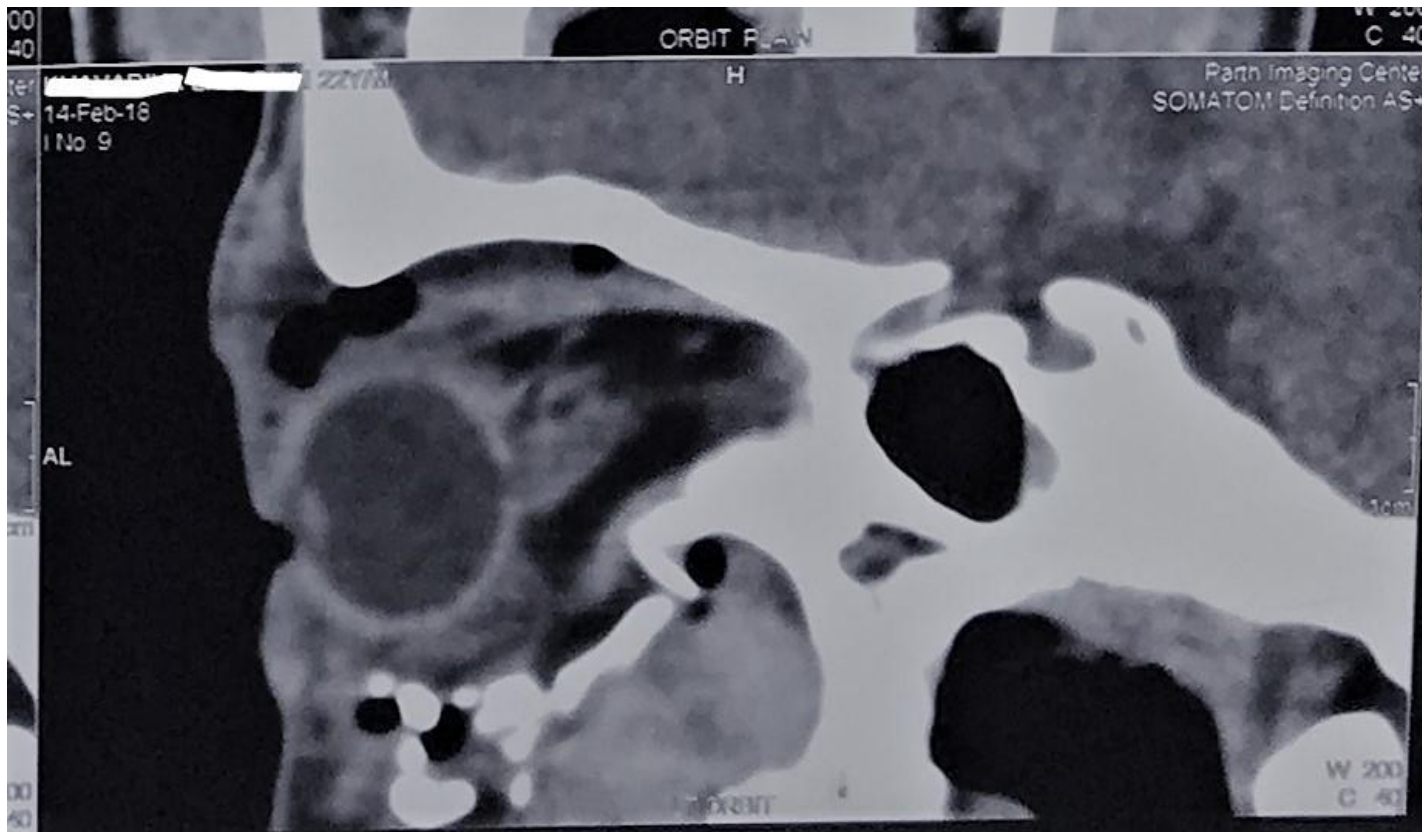
- Fundus photography LE suggestive of optic nerve head pulled anteriorly and lying in the vitreous with total detached retina.



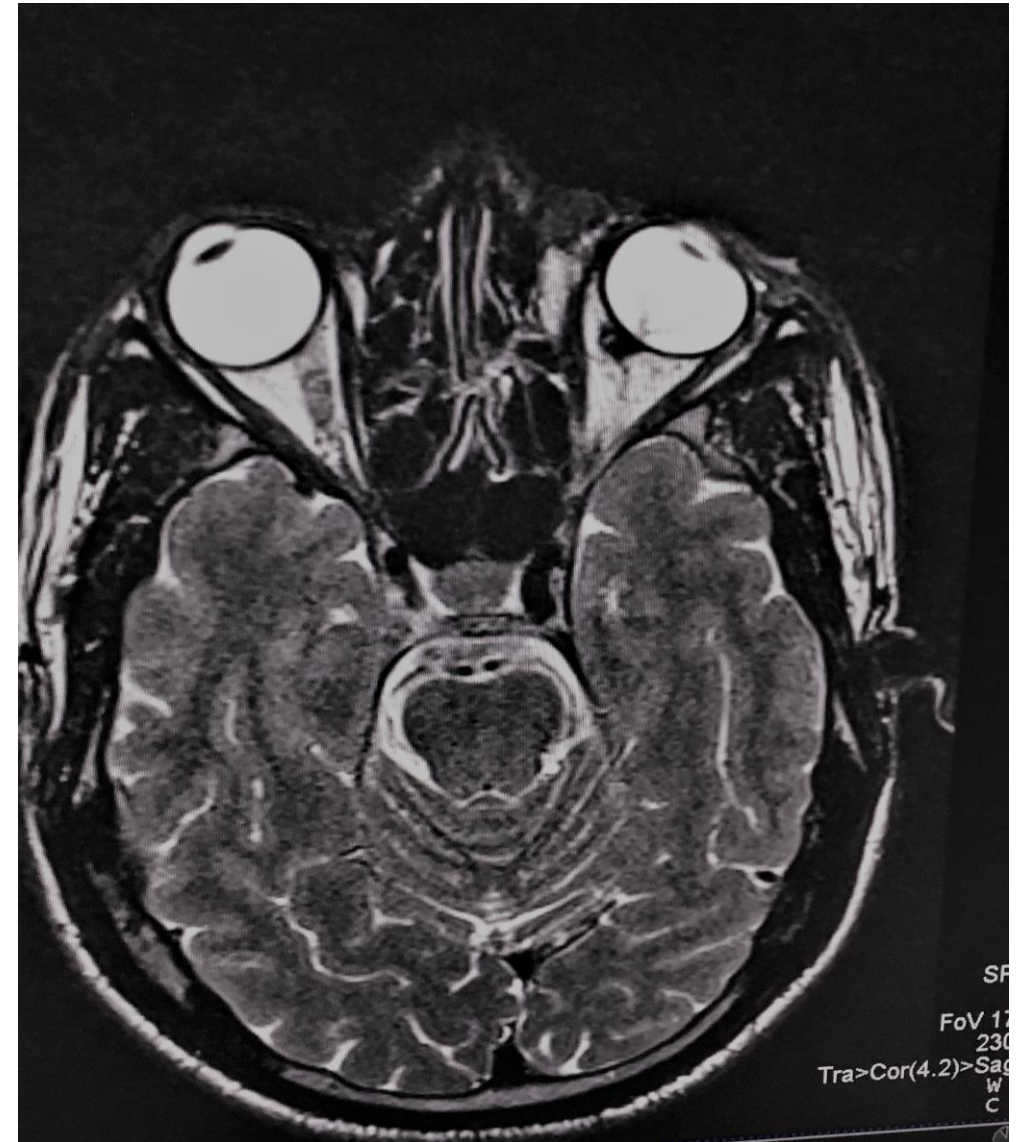
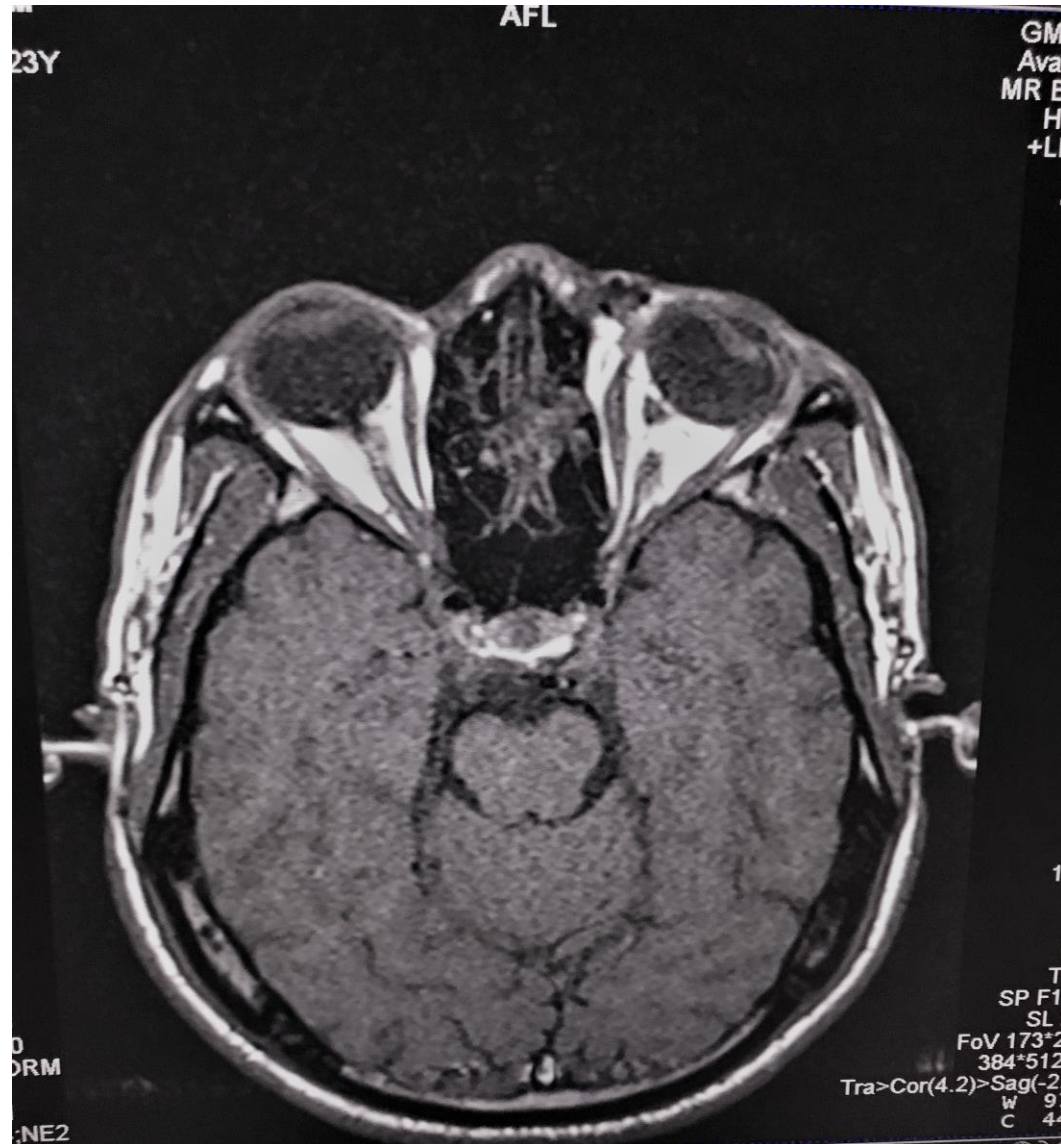
- USG B scan suggestive of LE retinal detachment



- CT scan findings suggestive of LE retrobulbar optic nerve transection and fracture of LE medial wall, lateral wall and floor of orbit and all walls of maxillary sinus on left side.



MRI findings suggestive of LE optic nerve transection



Conclusion

- Optic nerve transection is a rare presentation encountered in the patients of traumatic optic neuropathy.
- Differentiating it from other traumatic optic neuropathies is important in terms of preventing unnecessary treatment.